

Otitis Externa

Definition

Otitis externa results from inflammation of the epithelial lining of the external ear canal. The inflammation may arise within the external ear canal following, for example, grass seed penetration, or result from conditions affecting the ear flap or middle ear.

Etiology and pathogenesis

Otitis externa may result from many causes and it has proven useful to classify these as primary, predisposing, and secondary.

Primary factors directly induce inflammation within the external ear canal:

- **Hypersensitivities-allergies (most common)**
- Ear mites
- Foreign bodies
- Disorders of keratinization
- Autoimmune conditions
- Contact reactions to ear cleaners and medication
- Hypothyroidism, hyperadrenocorticism, and sex hormone dermatosis which can result in immunologic and cutaneous changes that result in ear infections.

Predisposing factors alter the environment within the external ear canal, which may result in quantitative and qualitative changes in otic microflora:

- Conformation
- Ear tumors or nasal-pharyngeal polyp formation, which obstruct the ear canal
- Errors in otic pharmacy or errors in the management of ear disease
- Environmental temperature and humidity, lifestyle (particularly swimming)

Perpetuating factors arise within the external ear canal as a consequence of primary or predisposing conditions:

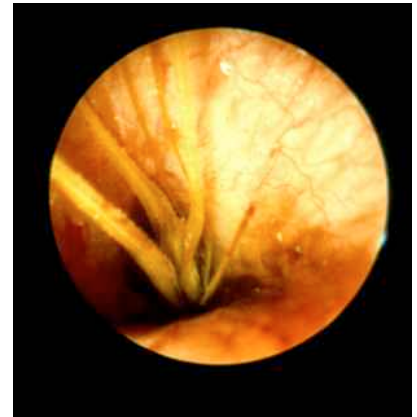- Changes in microflora leading to overgrowth and infection
- Middle ear infection
- Progressive changes in the ear epithelium and underlying cartilage

Clinical features

Clinical features will vary from individual to individual because of variation in primary cause, predisposing conditions, perpetuating factor, and individual expression.

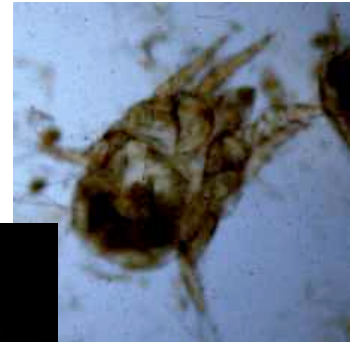
Foreign Bodies

Foreign bodies, particularly grass seeds, are usually easily seen on otoscopic examination, although in some cases the ear canal needs to be cleaned before they can be visualized.



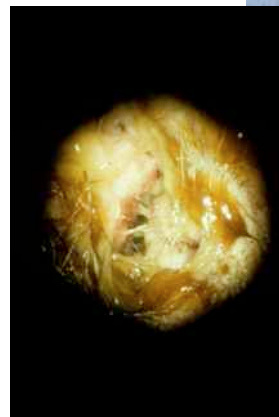
Ear Mites *Otodectes cynotis*

Infestation has a characteristic appearance and is associated with large amounts of dry, dark brown, waxy debris with variable amounts of inflammation. Careful otoscopic examination may allow for visualization of the mites as they move within the canal. Mites may also be seen on microscopic examination of scrapes from the external ear canal. Otodemodocosis (due to *Demodex canis*) is a rare cause of chronic otitis externa in the dog and cat.



Infection with *Staphylococcus* spp.,

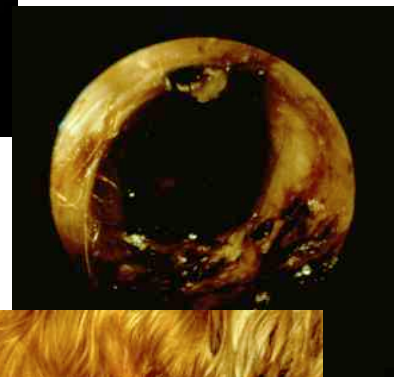
Streptococcus spp., and *Proteus* spp. is often, although not exclusively, associated with a light yellow exudate in most cases. The discharge progressively darker if there is concomitant wax production.



becomes

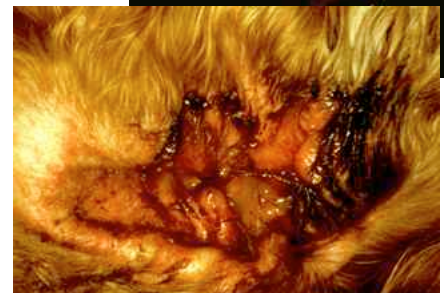Infection, particularly *Malassezia* spp., may result in a chocolate brown waxy discharge.

However, in some cases a more liquid discharge may be noted. In cats, *Malassezia* spp. have been associated with chronic pruritic otitis externa characterized by minimal discharge.

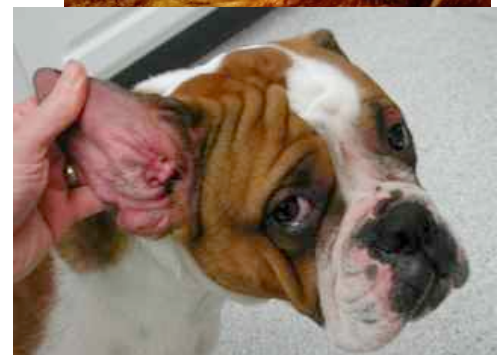

***Pseudomonas* spp.** are often found in ears that are very painful, inflamed, eroded, or ulcerated and have copious amounts of bright yellow to green, foul smelling exudate. This organism is more likely to be present if the case is chronic, although acute suppurative otitis due to *pseudomonas* spp. is not uncommon.

Allergies



Allergies (hypersensitivities) are one of the most common causes of chronic otitis externa, particularly in the dog. Early cases may exhibit redness and thickening of the skin on the inside of the ear flap and the vertical portion of the external ear canal. In these early cases the horizontal ear canal may appear quite normal. Most cases of allergies to air born substances or food allergies are associated with bilateral otitis externa, although unilateral ear disease may



be seen occasionally. Furthermore, although most cases in the dog will be associated with itching and clinical signs elsewhere (e.g. face, feet, and ventrum), a few dogs will present with otitis externa alone.

Defects in keratinization

These are often associated with chronic otitis externa. Some breeds (notably Cocker Spaniels) are prone to both otitis externa and idiopathic defects in keratinization. This is often accompanied by conformational problems such as narrow, hirsute ear canals. Most affected animals have generalized clinical signs.

Autoimmune diseases

These may be associated with pustules and crusts on the ear flap and lining of the ear canal. By far the most common of these diseases is pemphigus foliaceus, and the otic lesions may on rare occasions be confined to the pinnae and ear canal. More commonly there is extensive pustule and crust formation. The diseases which cause deeper lesions, such as pemphigus vulgaris and bullous pemphigoid, may cause ulceration in the ear canal, but will be associated with lesions elsewhere and systemic disease.

Chronic pathological changes

Whatever the cause of the otitis externa, the chronic changes to the external ear canal are associated with enlargement of the apocrine glands, thickening of the ear epithelium, a reduction in the effective diameter of the ear canal, decreased epidermal cell migration, and an increase in the humidity within the canal lumen. In severe, long-standing cases of otitis externa, chronic fibrosis and later bone formation of the external ear canal and associated cartilage may occur.

Differential diagnoses

The differential diagnoses for otitis externa are formulated on the basis of history, clinical examination, and the observation of any association, or otherwise, with systemic or generalized disease. Broadly, all primary and most predisposing conditions should be considered. The history and clinical signs must therefore be evaluated carefully.

Diagnostic tests

Appropriate diagnostic and laboratory procedures should be performed to rule in or out the various predisposing conditions.

Cytologic evaluation of ear exudates or debris should be the initial diagnostic procedure. The presence of cocci on smears is indicative of *Staphylococcus* spp. or *Streptococcus* spp., while the presence of gram-negative rods may indicate either *Pseudomonas* spp. or *Proteus* spp. Peanut-shaped yeast are characteristic of *Malassezia* spp., which are the most commonly found yeast in the ear. In addition to stained smears, debris from the ear canal can be mixed with mineral oil and examined for ectoparasites and their eggs or larvae.

Culture and sensitivity should be performed on ear exudate when the presence of gram-

negative rods is noted on cytology. This is because of the high likelihood of *Pseudomonas* spp., which can become resistant to a majority of antibacterial agents. Samples for culture and sensitivity should also be submitted when there has not been significant response to initial treatment.

Management

Predisposing conditions should receive appropriate treatment for the specific disease or factor. In-hospital Ear Cleaning - May be necessary initially if the ear is really dirty and sore or if the animal will not let the owner do a through cleaning at home. In many cases the animal will have to be sedated or anesthetized to perform the cleaning.

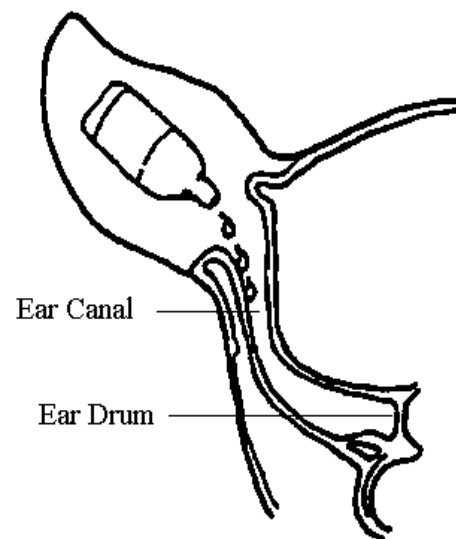
At-home Ear Cleaning

Periodic cleaning by the patient's owner is often necessary to remove secretions associated with continued inflammation or infection. The interval for this cleaning will vary from twice daily to weekly or longer, depending on the rate of accumulation of exudate or wax in the ear.

In home cleaning is especially important if *Pseudomonas* spp. are present. This is because ulceration of the canal results in increased rate of exudate formation and may necessitate cleaning once or twice daily. Flushing the ear with a bulb syringe containing cleaning agents is often very beneficial to obtain a thoroughly clean ear. The ear cleaning product dispensed will depend on the organism present, the type of exudate or wax present and the degree of redness and irritation of the ear canal.

Technique for At-Home Cleaning

- Grasp the ear flap and lift it into a vertical position.
- Pour ear cleaner into the ear until it completely fills the ear canal. Pour a few drops onto the ear flap itself.
- Next, fold the ear flap lengthwise on itself and gently rub the two halves together.
- Gently massage the ear canal in the the groove (behind the jawbone) from the base of the ear downward and then upward in order to dispense the ear cleaner throughout the ear canal. Continue massaging the ear canal in for 1-2 minutes. Then, clean out the excess cleaner and debris using a ball of cotton. If the cotton ball is dirty repeat the process until the cotton ball comes out clean with only the cleaning solution on it.



The cleaning procedure is very important. If the wax and debris are not routinely removed, the medication will be unable to reach the infected tissues and its effectiveness will be diminished.
Topical Treatment

Topical antibacterial treatment

Will depend on the bacteria present and their sensitivity.

Topical anti-inflammatory treatment

Many otic preparations contain steroids, which will benefit most cases of otitis externa by reducing itching, swelling, exudation, and narrowing of the ear canal. The exact product used will depend on specific changes in the ear canal.

Systemic anti-inflammatory treatment

Steroid pills may be administered for 10–14 days to reduce severe inflammation and swelling due to hypersensitivity states or the foreign body reaction that occurs due to rupture of cystic apocrine glands.

Systemic antibacterial agents are indicated when the tympanic membrane is ruptured and infection is present in the middle ear, or when there is poor response to topical treatment. Choice should be made according to culture and sensitivity results.

Indications for surgery

Surgery is indicated when a tumor or polyp is present in the ear canal or when the hyperplasia of the ear canal is so great the resulting stenosis precludes appropriate cleaning and application of medications.

Key points

- Impression smears of ear exudates should be done to determine which bacteria or yeast are present.
- **Because ear infections often secondary to other conditions, they often can just be controlled and not cured.**